

88 years  
Female Caucasian

Vent. rate 107 bpm  
PR interval \* ms  
QRS duration 120 ms  
QT/QTc 308/411 ms  
P-R-T axes \* 75 237

ID: 200506842 23-Aug-2015 21:54:55

Room: ER7  
Loc: 99

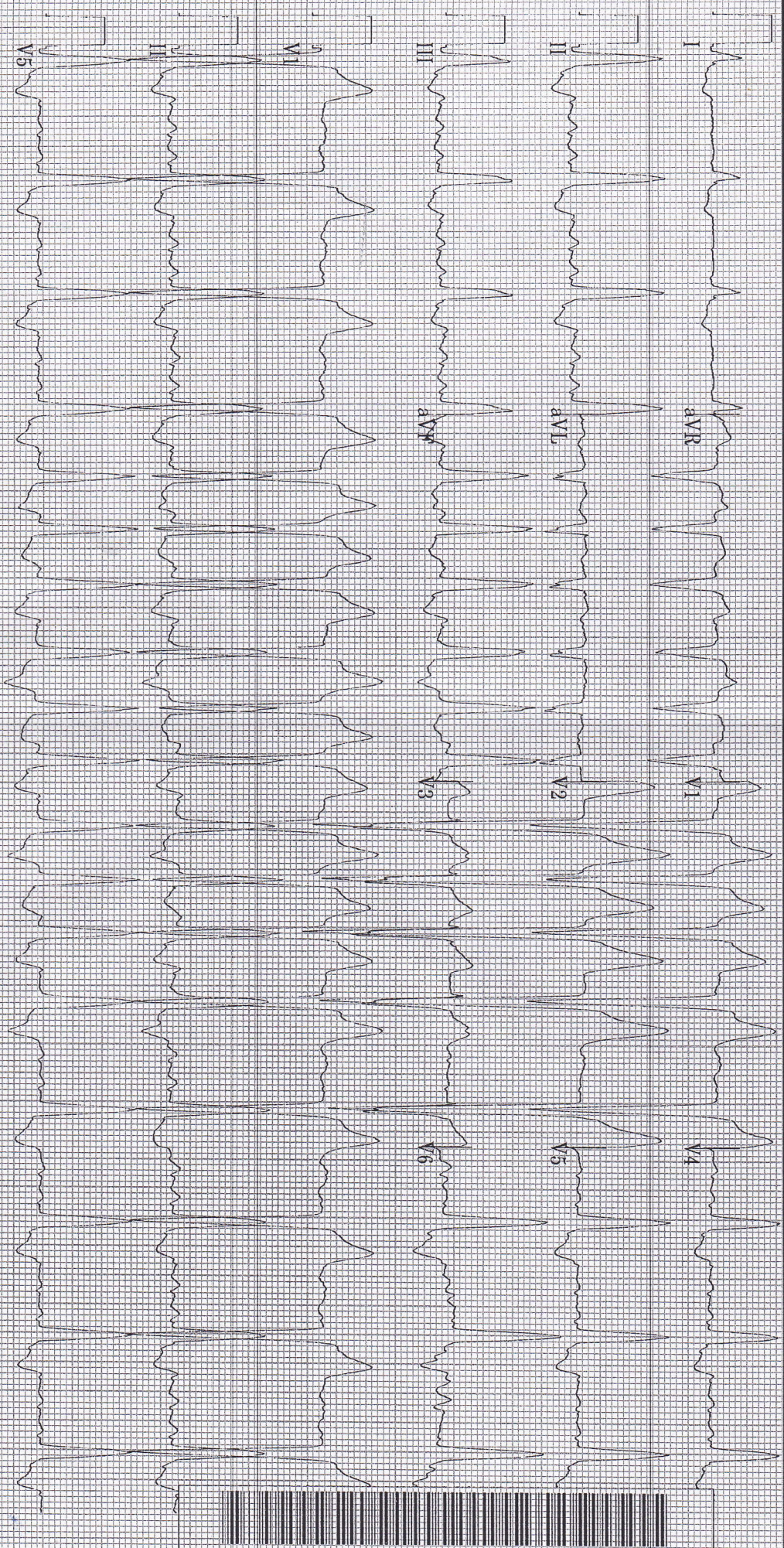
Technician: ~~ERB/ERB~~

#2

Atrial fibrillation with rapid ventricular response  
Left ventricular hypertrophy with QRS widening  
Cannot rule out Septal infarct, age undetermined  
ST & T wave abnormality, consider inferolateral ischemia or digitalis effect

Referred by: ERM D

Unconfirmed



150 Hz 25.0 mm/s 10.0 mm/mV

4 by 2.5s + 3 rhythm tabs

MAC55-009A

12SL™ V237

COVIDIEN Kendall

0645

Printed in USA

